



Journal of Health and Medical Sciences

Gonzales, P. N. G., Villaraza, S. G., & Punzalan-Sotelo, A. M. (2022), Guillain-Barré Syndrome: A Case Report of Post Covid-19 Vaccination in the Philippines. *Journal of Health and Medical Sciences*, 5(3), 276-282.

ISSN 2622-7258

DOI: 10.31014/aior.1994.05.03.237

The online version of this article can be found at:

<https://www.asianinstituteofresearch.org/>

Published by:
The Asian Institute of Research

The *Journal of Health and Medical Sciences* is an Open Access publication. It may be read, copied, and distributed free of charge according to the conditions of the Creative Commons Attribution 4.0 International license.

The Asian Institute of Research *Journal of Health and Medical Sciences* is a peer-reviewed International Journal. The journal covers scholarly articles in the fields of Medicine and Public Health, including medicine, surgery, ophthalmology, gynecology and obstetrics, psychiatry, anesthesia, pediatrics, orthopedics, microbiology, pathology and laboratory medicine, medical education, research methodology, forensic medicine, medical ethics, community medicine, public health, community health, behavioral health, health policy, health service, health education, health economics, medical ethics, health protection, environmental health, and equity in health. As the journal is Open Access, it ensures high visibility and the increase of citations for all research articles published. The *Journal of Health and Medical Sciences* aims to facilitate scholarly work on recent theoretical and practical aspects of Health and Medical Sciences.



ASIAN INSTITUTE OF RESEARCH
Connecting Scholars Worldwide

Guillain-Barré Syndrome: A Case Report of Post Covid-19 Vaccination in the Philippines

Paul Nichol G. Gonzales¹, Steven G. Villaraza², Aubrey M. Punzalan-Sotelo³

^{1,2,3} Jose R. Reyes Memorial Medical Center, Department of Neurology

Abstract

Guillain-Barré Syndrome (GBS) is a complex autoimmune disorder where a person's own immune system damages the nerve and is usually characterized by ascending symmetrical weakness of the upper and lower extremities (Wijdicks & Klein, 2017). It is a rare condition and the worldwide frequency of GBS is only 2 in 100,000 adult individuals (McGrogan et al., 2009). Studies have shown its association with different vaccines but in these pandemic times, there is a lack of literature on post-COVID-19 vaccination-associated GBS. We report a case of a 68-year-old male from Caloocan City with an initial complaint of febrile illness followed by distal lower extremity weakness which started seven (7) days after the patient received his first Sinovac-CoronaVac vaccine. We report a case of GBS that is related to the Sinovac-CoronaVac vaccine which adds to the body of literature that is currently available and may reflect a possible link.

Keywords: Guillain-Barre, Covid-19, Vaccination

1. Introduction

Originating in Wuhan, China last December 2019, the COVID-19 pandemic caused by the causative agent severe acute respiratory syndrome (SARS-CoV-2) dramatically affected the world population (Omer et al., 2020). To reduce the transmissibility of the disease, the role of vaccination is now taking center stage in high resource countries, especially as older and more vulnerable populations have been vaccinated. Worldwide, several patients have been reported to experience pain in the vaccination site, to a more serious anaphylactic shock (Salmon et al., 2013). Neurological complications after COVID-19 vaccinations are very rare, and only a few cases have been reported, where an article published February 2021 reported the first case of Guillain-Barré Syndrome (GBS) after the first dose of Pfizer COVID-19 vaccine in Florida (Khan et al., 2022).

GBS is a rare but serious post-infectious immune-mediated neuropathy, and it results from the auto-immune destruction of nerves in the peripheral nervous system. The disease is rare, with the incidence rate of 0.6 to 4 per 100,000 individuals (R. A. C. Hughes, 1990). Bilateral leg weakness is the most common early motor symptom, and pain is the most common non-motor symptom (Forsberg et al., 2004). Neurological adverse events following immunization may be caused by the active antigen in the vaccine or other constituents, such as adjuvants, or may merely be coincidental (Miravalle et al., 2010).

This report presents the case of a 68-year-old man from Caloocan City, with a first-ever complaint of bilateral lower extremity weakness seen last August 15, 2021, 13 days after his first dose of Sinovac-CoronaVac vaccine.

2. Case Report

We report a case of a 68-year-old man who presented at the emergency room of Jose R. Reyes Memorial Medical Center, Manila with bilateral lower extremity weakness last August 15, 2021. The patient had his first dose of Sinovac-CoronaVac vaccine on August 2, 2021. Three days after receiving the first dose, he started having undocumented febrile episodes. Four days after, the febrile episodes subsided but the patient started to have weakness of both lower extremities described as dragging of either foot upon ambulation. After two more days, there was progression of bilateral lower extremity weakness described as difficulty getting up from bed or standing up from sitting position. There was no observed weakness of the upper extremities. Few days before admission, he was unable to sit independently and was bedridden. He also had onset of cough and colds, with occasional episodes of difficulty of breathing. Consultation was sought via telemedicine to which COVID-19 reverse transcription polymerase chain reaction test was requested, and results were negative. He was then advised admission for further evaluation and management.

Upon arrival at the emergency room, the patient's blood pressure, heart rate, respiratory rate, and temperature were within normal limits. Oxygen saturation was 98-99% at room air. He was awake but follows commands inconsistently. Pertinent general physical examination included auscultatory findings of crackles on both lungs. Digital rectal examination revealed a full rectal vault and a lax sphincteric tone. Pertinent neurologic findings included a 5/5 motor strength on the upper extremities, and a 3/5 motor strength in both lower extremities using the Medical Research Council Manual Muscle Testing scale. On sensory examination, the patient perceived pain in both lower extremities however, quantification of sensory deficit by percentage cannot be fully determined as the patient was illiterate. Deep tendon reflexes for bilateral patella and Achilles were absent.

Laboratory examination yielded normal values for the complete blood count, serum sodium and potassium, and creatinine levels. An electrocardiogram revealed atrial fibrillation in controlled ventricular response. Chest x-ray was done revealing a right lower lung pneumonia with minimal pleural effusion. The patient was started on Azithromycin 500mg tablet per ore once a day and Ceftriaxone 2gm via intravenous route once a day. Lumbar puncture was done, and the Cerebrospinal Fluid (CSF) analysis revealed a colorless clear fluid, with albuminocytologic dissociation (see Table 1). A nerve conduction study was done with an impression of an acute inflammatory demyelinating (see Figures 1-4).

An impression of GBS, acute inflammatory demyelinating polyneuropathy was considered. Intravenous immunoglobulin (IVIg) infusion was requested. The patient's motor strength spontaneously improved starting three days after admission where he could eventually ambulate with assistance. He was eventually discharged on the tenth hospital stay with an Erasmus GBS Outcome Score score of 4, and was advised for follow up. Follow-up was done after three months, and the patient had no residual deficits and was independent in all activities of daily living.

3. Discussion

GBS is considered as a severe auto-immune disease that mainly affects the majority of the spinal nerve roots and peripheral nerves and may involve the cranial nerves. The initial symptoms of the disease include symmetrical weakness of the extremities, and it quickly aggravates and spreads from a distal to proximal fashion. The disease is usually preceded by infection or other immune stimulation that induces an aberrant auto-immune response, and it targets the peripheral nerves, which explains the weakness of extremities (R. A. Hughes & Cornblath, 2005). The molecular mimicry between microbial and nerve antigens is a major force that drives behind the development of the disorder. In this case, the patient presents an association between GBS and his recent vaccination, as the onset of the disease started seven days after the first dose of Sinovac-CoronaVac vaccine.

The patient is a 68-year-old male with initial complaints of weakness of the distal lower extremities, and progressed up to the entire lower extremities, which had a temporal proximity from a recent vaccination with Sinovac-CoronaVac vaccine and was the likely trigger for the onset of the symptoms. In several reported cases, the presence

of diarrhea within two weeks before the disease can predict the patient's outcome for GBS (Walgaard et al., 2011). The patient however did not present with any gastro-intestinal symptoms prior to the onset of weakness. Among the triggering factors, vaccines are reported to be associated with onset of GBS (Haber et al., 2009). Vaccine-associated GBS is defined as the onset of GBS symptoms within the six-week period after receiving the vaccine (Sejvar et al., 2011). Known COVID-19 vaccines worldwide include Pfizer-BioNTech, Moderna, Oxford Astrazeneca, Johnson and Johnson, and Sinovac (Khan et al., 2022). A systematic review by Shao et al., (2021) found only 17 publications reporting 39 cases of post-vaccination GBS. Most of the reported cases received AstraZeneca vaccine. Others included, in descending order: Pfizer, Johnson and Johnson, and Sinovac Biotech. The review also investigated the GBS rate after COVID-19 vaccination ranged from 1.8 to 53.2 cases/ 1 million doses.

In our patient, the onset of GBS started seven days after his first shot of Sinovac Vaccine, and findings also indicated a strong association between the two. The first case of GBS following COVID-19 vaccination was reported in February 2021 (Khan et al., 2022), with an elderly female from Florida, USA who presented with GBS symptoms two weeks after the first dose of Pfizer vaccine. The patient presented with fatigue and bilateral symmetric weakness of the lower limbs, and CSF analysis indicated albuminocytological dissociation. The woman was started on IVIg which contributed to the improvement of the disease and was discharged to a rehabilitation institute (Waheed et al., 2021). Considering the uncertainty of the causal relationship between vaccines and GBS and the lack of evidence that proves their relation, a temporal association is possible. However, further studies are required before establishing strong conclusions.

During the hospitalization and treatment course of the patient, the patient's motor strength spontaneously improved three days after admission owing to the self-limiting nature of GBS. IVIg infusion was deferred since the patient's condition spontaneously improved. IVIg is indicated to those who show rapid progression of weakness, respiratory insufficiency, severe autonomic or swallowing dysfunction, and unable to walk independently (Leonhard et al., 2019). According to Cochrane review of trials, within the first two weeks from the onset of weakness, GBS should be treated with IVIg or plasmapheresis if indicated. The administration of IVIg for five consecutive days was able to provide relief. The Cochrane review of trials indicated IVIg as a great replacement for plasma exchange, showing statistics on the increased use of IVIg due to its convenience and availability (R. A. Hughes et al., 2006). Although the best option for treatment depends on the patient's prognosis, eligible patients should be treated right away as lack of treatment is thought to have a prolonged immune response that causes persistent nerve damage that may require treatment for a longer period of time (Visser et al., 1998). The longer interval between the onset and treatment, as well as the longer time to nadir, can be both associated with a greater chance of relapse.

4. Conclusion

GBS is a rare, autoimmune disorder characterized by acute onset of ascending motor and/or sensory deficits and is found to be a common cause of paralysis if left untreated for a long time. GBS following COVID-19 vaccine is an adverse event of special interest due to implementation of mass vaccination in the country. Although extremely rare, the occurrence of post-COVID-19 vaccine GBS presents a potentially devastating neurologic emergency, and vigilant surveillance of this adverse event is strongly warranted as more people become vaccinated. The author hopes that this case will serve as a bridge to further research on this subject and will foster awareness on a possible onset of GBS after receiving the COVID-19 vaccine, and the emergent need for intervention should a case arise.

Table 1: Cerebrospinal (CSF) fluid analysis

| | |
|---------------------|---|
| Color | Colorless |
| Transparency | Clear |
| Volume | 2 mL |
| RBC Count | None found |
| WBC Count | 1 mm³ |
| CSF Protein | 245mg/dL (Normal: 15–50 mg/dL) |

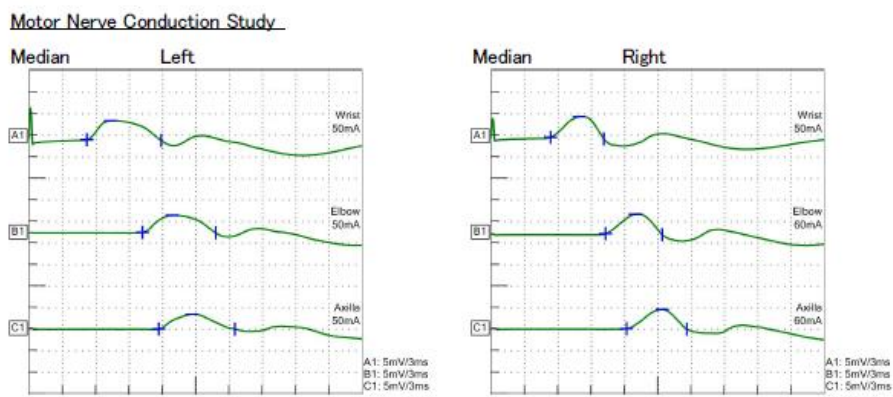


Figure 1: The left and right median motor nerve conduction studies which showed prolonged distal latencies, normal amplitudes, and normal conduction velocities

Sensory Nerve Conduction Study

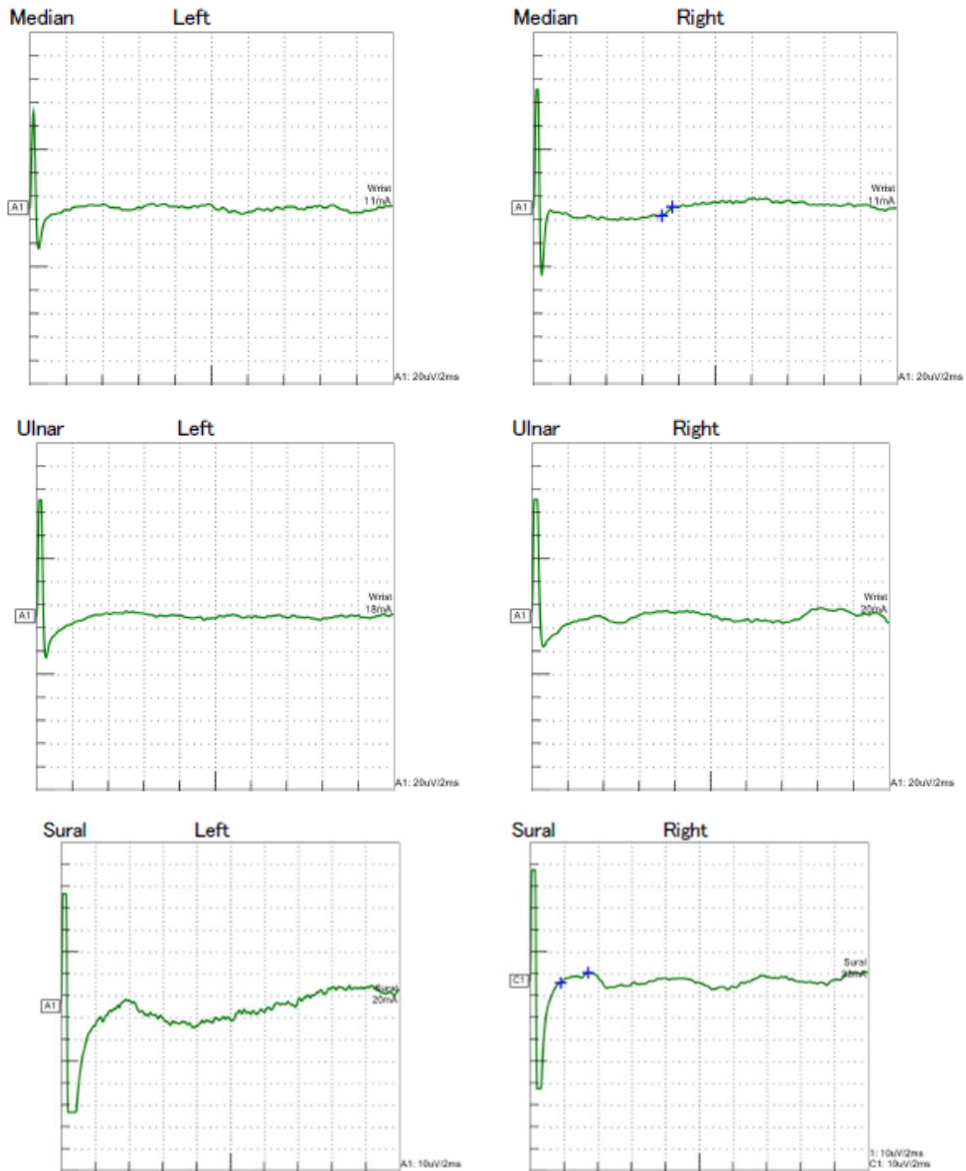


Figure 2: The left and right ulnar sensory nerve, median sensory nerve, and sural sensory nerve conduction studies showed no recordable response

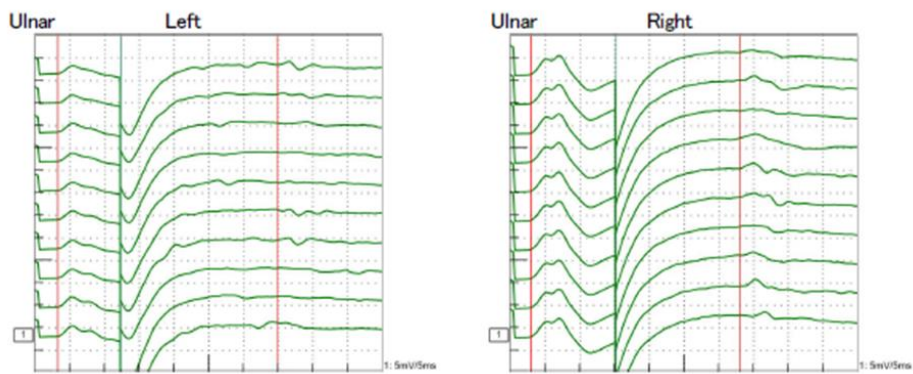


Figure 3: The F-wave latencies on left and right ulnar nerves are prolonged

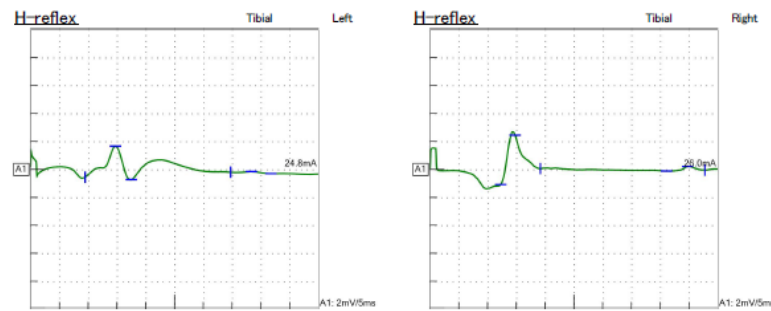


Figure 4: The H-reflex latencies are prolonged

References

- Forsberg, A., Press, R., Einarsson, U., de Pedro-Cuesta, J., & Widén Holmqvist, L. (2004). Impairment in Guillain-Barré syndrome during the first 2 years after onset: A prospective study. *Journal of the Neurological Sciences*, 227(1), 131–138. <https://doi.org/10.1016/j.jns.2004.09.021>
- Haber, P., Sejvar, J., Mikaeloff, Y., & DeStefano, F. (2009). Vaccines and Guillain-Barré Syndrome: *Drug Safety*, 32(4), 309–323. <https://doi.org/10.2165/00002018-200932040-00005>
- Hughes, R. A. C. (1990). Pathology of Guillain-Barré Syndrome. In M. Swash (Ed.), *Guillain-Barré Syndrome* (pp. 83–100). Springer London. https://doi.org/10.1007/978-1-4471-3175-5_4
- Hughes, R. A., & Cornblath, D. R. (2005). Guillain-Barré syndrome. *The Lancet*, 366(9497), 1653–1666. [https://doi.org/10.1016/S0140-6736\(05\)67665-9](https://doi.org/10.1016/S0140-6736(05)67665-9)
- Hughes, R. A., Swan, A. V., van Koningsveld, R., & van Doorn, P. A. (2006). Corticosteroids for Guillain-Barré syndrome. In The Cochrane Collaboration (Ed.), *Cochrane Database of Systematic Reviews* (p. CD001446.pub2). John Wiley & Sons, Ltd. <https://doi.org/10.1002/14651858.CD001446.pub2>
- Khan, Z., Ahmad, U., Ualiyeva, D., Amisshah, O. B., Khan, A., Noor, Z., & Zaman, N. (2022). Guillain-Barre syndrome: An autoimmune disorder post-COVID-19 vaccination? *Clinical Immunology Communications*, 2, 1–5. <https://doi.org/10.1016/j.clicom.2021.12.002>
- Leonhard, S. E., Mandarakas, M. R., Gondim, F. A. A., Bateman, K., Ferreira, M. L. B., Cornblath, D. R., van Doorn, P. A., Dourado, M. E., Hughes, R. A. C., Islam, B., Kusunoki, S., Pardo, C. A., Reisin, R., Sejvar, J. J., Shahrizaila, N., Soares, C., Umapathi, T., Wang, Y., Yiu, E. M., ... Jacobs, B. C. (2019). Diagnosis and management of Guillain-Barré syndrome in ten steps. *Nature Reviews Neurology*, 15(11), 671–683. <https://doi.org/10.1038/s41582-019-0250-9>
- McGrogan, A., Madle, G. C., Seaman, H. E., & de Vries, C. S. (2009). The Epidemiology of Guillain-Barré Syndrome Worldwide. *Neuroepidemiology*, 32(2), 150–163. <https://doi.org/10.1159/000184748>
- Miravalle, A., Biller, J., Schnitzler, E., & Bonwit, A. (2010). Neurological complications following vaccinations. *Neurological Research*, 32(3), 285–292. <https://doi.org/10.1179/016164110X12645013515214>
- Omer, S. B., Yildirim, I., & Forman, H. P. (2020). Herd Immunity and Implications for SARS-CoV-2 Control. *JAMA*, 324(20), 2095. <https://doi.org/10.1001/jama.2020.20892>
- Salmon, D. A., Proschan, M., Forshee, R., Gargiullo, P., Bleser, W., Burwen, D. R., Cunningham, F., Garman, P., Greene, S. K., Lee, G. M., Vellozzi, C., Yih, W. K., Gellin, B., & Lurie, N. (2013). Association between Guillain-Barré syndrome and influenza A (H1N1) 2009 monovalent inactivated vaccines in the USA: A meta-analysis. *The Lancet*, 381(9876), 1461–1468. [https://doi.org/10.1016/S0140-6736\(12\)62189-8](https://doi.org/10.1016/S0140-6736(12)62189-8)
- Sejvar, J. J., Kohl, K. S., Gidudu, J., Amato, A., Bakshi, N., Baxter, R., Burwen, D. R., Cornblath, D. R., Cleerhout, J., Edwards, K. M., Heininger, U., Hughes, R., Khuri-Bulos, N., Korinthenberg, R., Law, B. J., Munro, U., Maltezou, H. C., Nell, P., Oleske, J., ... Wiznitzer, M. (2011). Guillain-Barré syndrome and Fisher syndrome: Case definitions and guidelines for collection, analysis, and presentation of immunization safety data. *Vaccine*, 29(3), 599–612. <https://doi.org/10.1016/j.vaccine.2010.06.003>
- Shao, S.-C., Wang, C.-H., Chang, K.-C., Hung, M.-J., Chen, H.-Y., & Liao, S.-C. (2021). Guillain-Barré Syndrome Associated with COVID-19 Vaccination. *Emerging Infectious Diseases*, 27(12), 3175–3178. <https://doi.org/10.3201/eid2712.211634>
- Visser, L., van der Meche, F., Meulstee, J., van Doorn, P., & the Dutch Guillain-Barre study group. (1998). Risk factors for treatment related clinical fluctuations in Guillain-Barre syndrome. *Journal of Neurology, Neurosurgery & Psychiatry*, 64(2), 242–244. <https://doi.org/10.1136/jnnp.64.2.242>
- Waheed, S., Bayas, A., Hindi, F., Rizvi, Z., & Espinosa, P. S. (2021). Neurological Complications of COVID-19: Guillain-Barre Syndrome Following Pfizer COVID-19 Vaccine. *Cureus*. <https://doi.org/10.7759/cureus.13426>

- Walgaard, C., Lingsma, H. F., Ruts, L., van Doorn, P. A., Steyerberg, E. W., & Jacobs, B. C. (2011). Early recognition of poor prognosis in Guillain-Barre syndrome. *Neurology*, 76(11), 968–975. <https://doi.org/10.1212/WNL.0b013e3182104407>
- Wijdicks, E. F. M., & Klein, C. J. (2017). Guillain-Barré Syndrome. *Mayo Clinic Proceedings*, 92(3), 467–479. <https://doi.org/10.1016/j.mayocp.2016.12.002>