



# Journal of Health and Medical Sciences

**Mejdoubi, A., Khouali, M., Al Dohni, Y., Oulali, N., & Moufid, F. (2022),  
Calvarial Metastasis with Dural Sinus Invasion: A Case Report. *Journal of  
Health and Medical Sciences*, 5(3), 237-240.**

ISSN 2622-7258

DOI: 10.31014/aior.1994.05.03.232

The online version of this article can be found at:  
**<https://www.asianinstituteofresearch.org/>**

Published by:  
The Asian Institute of Research

The *Journal of Health and Medical Sciences* is an Open Access publication. It may be read, copied, and distributed free of charge according to the conditions of the Creative Commons Attribution 4.0 International license.

The Asian Institute of Research *Journal of Health and Medical Sciences* is a peer-reviewed International Journal. The journal covers scholarly articles in the fields of Medicine and Public Health, including medicine, surgery, ophthalmology, gynecology and obstetrics, psychiatry, anesthesia, pediatrics, orthopedics, microbiology, pathology and laboratory medicine, medical education, research methodology, forensic medicine, medical ethics, community medicine, public health, community health, behavioral health, health policy, health service, health education, health economics, medical ethics, health protection, environmental health, and equity in health. As the journal is Open Access, it ensures high visibility and the increase of citations for all research articles published. The *Journal of Health and Medical Sciences* aims to facilitate scholarly work on recent theoretical and practical aspects of Health and Medical Sciences.



ASIAN INSTITUTE OF RESEARCH  
Connecting Scholars Worldwide

# Calvarial Metastasis with Dural Sinus Invasion: A Case Report

Anasse Mejdoubi<sup>1</sup>, Mohamed Khouli<sup>2</sup>, Younes Al Dohni<sup>3</sup>, Nouredine Oulali<sup>4</sup>, Fayçal Moufid<sup>5</sup>

<sup>1,2,3,4,5</sup>Department of Neurosurgery, Mohammed VI University Hospital, Faculty of Medicine, Mohammed First University, Oujda, Morocco

Correspondence: Anasse Mejdoubi. Email: anasse.mejdoubi@gmail.com / Phone: (+212)661368832  
ORCID ID: 0000-0001-9805-3781

## Abstract

Metastatic disease to the calvaria with invasive dural venous sinus extension presents unique diagnostic and management challenges in cancer patients. Treatment options are not standardized. We report a case of a 62-year-old female who presented with breast cancer calvarial metastasis and upper sagittal sinus extension, and in whom a complete resection of the lesion was performed. Surgery may be helpful in selected cancer patients for symptomatic relief as well as survival benefits.

**Keywords:** Calvarial Metastasis, Dural Sinus Invasion, Surgical Treatment

## 1. Introduction

Metastases are the most common malignancies of the central nervous system. Rising incidence is due to the availability of more advanced neuroimaging techniques and raising survival rate (Newton, 2008; Takei et al., 2016). Unfavourable prognosis, high morbidity and mortality are associated with central nervous system metastases (Nayak et al., 2009). Skull metastases remain a neglected complication and are of less clinical importance than brain metastases (Harrison et al., 2018; Mitsuya et al., 2011). Their precise incidence is underreported in the literature. Few studies have been published on skull metastases in the literature (Harrison et al., 2018; Nasi-Kordhishti et al., 2021; Ozgiray et al., 2016; Stark et al., 2003). Multiple therapeutic modalities are used in the treatment of cranial metastases: radiotherapy, surgery, and chemotherapy. However, no treatment standard has been developed (Harrison et al., 2018).

## 2. Case presentation

A 62 years old female patient has operated two years ago for invasive ductal carcinoma. She has had a tumorectomy followed by radiotherapy and hormonotherapy. Our patient came to the clinic complaining of a headache, and calvaria mass started to appear for six months. Clinical examination revealed a painful frontal calvarial mass. Computed tomography (CT) scan revealed an osteolytic lesion in the frontal bone with endocranial

extension. Magnetic resonance imaging (MRI) showed (figure 1) a midline process, with exo and endocranial extension, measuring 53 \* 45 \* 30mm. The lesion is intermediate signal T1 and T2 and is enhanced after Gadolinium injection, with dura mater contrast enhancement and thrombosis of the upper sagittal sinus.

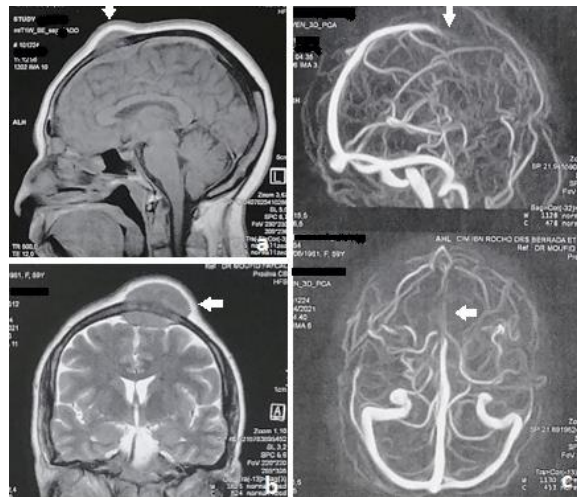


Figure 1: Preoperative cerebral MRI. **a** Sagittal T1-weighted image shows a bone lesion with exo and endocranial extension. **b** Coronal T2-weighted image shows superior sagittal sinus infiltration. **c** MRI-angiogram shows obstruction of the anterior third of the superior sagittal sinus.

The whole-body CT scan investigation did not show other metastases. The patient underwent a complete tumor resection by piecemeal technique (figure 2) with superior sagittal sinus resection and cranioplasty.

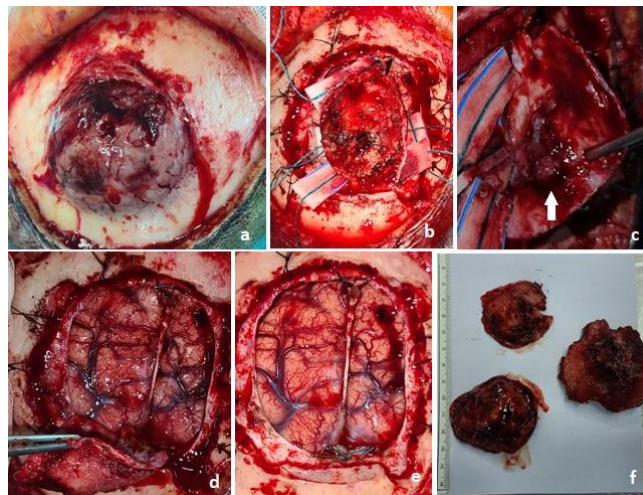


Figure 2: Peroperative image. **a** Extracranial calvarial metastasis. **b** and **c** Dural metastasis with sous dural invasion. **d** and **e** Resection of metastasis after ligation of the upper sagittal sinus. **f** Macroscopic aspect of the tumor after resection by piecemeal technique.

Postoperative MRI showed complete resection (figure 3). The histological examination showed poorly differentiated breast carcinoma. The patient had 30 sessions of skull radiation. Our patient is in good condition without any complications after one year of treatment.

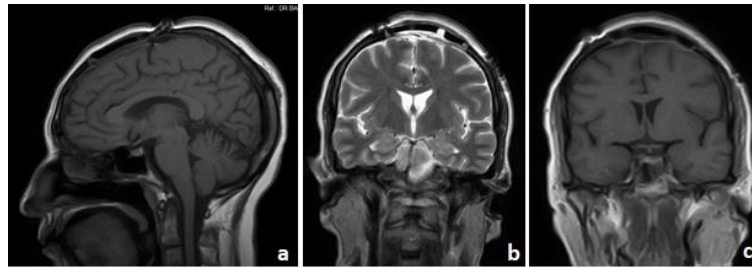


Figure 3: Postoperative cerebral MRI. **a** Sagittal T1-weighted image, **b** Coronal T2-weighted image, and **c** Coronal T1-weighted with contrast image shows complete resection of the tumor.

### 3. Discussion

Breast, prostate, and lung cancer are the most common primary tumors associated with cranial metastases (Harrison et al., 2018; Newton, 2008). 24% of breast cancer patients have metastatic skull lesions (Heo et al., 2017). Metastatic involvement of the dura mater is a rare event and usually arises by direct extension from skull metastases (Heo et al., 2017; Laigle-Donadey et al., 2005). Calvarial metastases are most commonly asymptomatic. When symptomatic, they most often manifest as a mass under the scalp with local pain. In a series reported by Michael et al. (Michael et al., 2001), 70% of patients present a local mass as the initial symptom. Invasive metastases can manifest as headache, vomiting, or even neurological deficits (Harrison et al., 2018; Nasi-Kordhishti et al., 2021; Newton, 2008; Ozgiray et al., 2016).

MRI remains the test of choice to explore skull metastases. MRI can be used to assess soft tissue involvement and intracranial extension. Calvarial metastases often present as osteolytic lesions (Harrison et al., 2018; Mitsuya et al., 2011). Mitsuya proposed an MRI classification based on three questions: concerning the location (either in the calvarium or in the cranial base), concerning distribution within the plan of the cranial bone (circumscribed or diffuse), and concerning invasion (intraosseous or invasive) (Mitsuya et al., 2011).

Four therapeutic modalities should be considered: irradiation, chemotherapy, hormonal therapy, and surgical resection. The treatment of skull metastases is most often palliative. In cases of solitary metastasis, the treatment should be considered for curative purposes. Radiotherapy is the first option. In diffuse cranial lesions, whole brain radiation therapy is often necessary. In oligo metastatic forms, it is reasonable to consider focused radiotherapy such as radiosurgery. Radiosurgery provides better tumor control with side effects comparable with those of standard radiation therapy (Mitsuya et al., 2011). Surgical treatment is poorly described in the literature. Only a minority of patients with skull metastases are candidates for surgical resection. Complete gross total resection is associated with a prolonged survival rate (Harrison et al., 2018; Nasi-Kordhishti et al., 2021). The tumor can be removed *en bloc* or using the piecemeal technique. The *en bloc* resection technique is based on the method described by Kinjo to ensure complete resection of meningiomas that invade the skull or the soft tissues. Michael et al. have extended this technique to include the dural sinus. *En bloc* resection is more effective in limiting operative blood loss (Michael et al., 2001). Dural sinus invasion increases the complexity of the surgery, however, more aggressive resection surgery is recommended and is associated with low morbidity (Harrison et al., 2018; Newton, 2008; Ozgiray et al., 2016). Surgery should be indicated in case of (Harrison et al., 2018; Ozgiray et al., 2016; Sawaya, 1997; Stark et al., 2003): - the presence of a neurological deficit - massive bone destruction, infiltration of the dura - painful mass - single metastases - diagnostic confirmation. The involvement of the venous sinus does not seem to affect the indications for surgical intervention. It is recommended for sinus resection selection patients that the tumor is localized in the anterior third of the sagittal sinus or that the sinus is occluded on imaging. Michael et al. concluded that surgery was a relatively safe and effective treatment option (Michael et al., 2001). Reconstruction of bone defects is usually performed simultaneously as resection surgery but can be delayed from a few weeks to a few months (Harrison et al., 2018; Ozgiray et al., 2016). Depending on the type of tumor, the use of hormone therapy, targeted therapy, or conventional chemotherapy may be appropriate. Recent advances in chemotherapy have contributed to the treatment of metastatic skull tumors and systemic bone metastases (Harrison et al., 2018).

## 5. Conclusion

Metastatic disease to the calvaria with intracranial dural sinus invasion presents unique diagnosis and management challenges in cancer patients. The management should be multidisciplinary. A complete resection must be sought after a proper investigation and appropriate neurosurgical plan. Surgical resection undoubtedly cannot influence the underlying disease but enables the patient to avoid local pain, and it might improve neurologic symptoms with low morbidity and mortality.

## Acknowledgments

Consent for publication: The patient has signed an informed consent for the publication of their data and photographs.

Funding: The authors have no relevant financial or non-financial interests to disclose.

Declaration of competing interest: The authors declare that they have no conflict of interest.

## References

- Harrison, R. A., Nam, J. Y., Weathers, S. P., & DeMonte, F. (2018). Intracranial dural, calvarial, and skull base metastases. In *Handbook of Clinical Neurology* (1st ed., Vol. 149). <https://doi.org/10.1016/B978-0-12-811161-1.00014-1>
- Heo, M. H., Cho, Y. J., Kim, H. K., Kim, J. Y., & Park, Y. H. (2017). Isolated pachymeningeal metastasis from breast cancer: Clinical features and prognostic factors. *Breast*, *35*, 109–114. <https://doi.org/10.1016/j.breast.2017.07.006>
- Laigle-Donadey, F., Taillibert, S., Mokhtari, K., Hildebrand, J., & Delattre, J. Y. (2005). Dural metastases. *Journal of Neuro-Oncology*, *75*(1), 57–61. <https://doi.org/10.1007/s11060-004-8098-1>
- Michael, C. B., Gokaslan, Z. L., DeMonte, F., McCutcheon, I. E., Sawaya, R., & Lang, F. F. (2001). Surgical resection of calvarial metastases overlying dural sinuses. *Neurosurgery*, *48*(4), 745–755. <https://doi.org/10.1227/00006123-200104000-00009>
- Mitsuya, K., Nakasu, Y., Horiguchi, S., Harada, H., Nishimura, T., Yuen, S., ... Endo, M. (2011). Metastatic skull tumors: MRI features and a new conventional classification. *Journal of Neuro-Oncology*, *104*(1), 239–245. <https://doi.org/10.1007/s11060-010-0465-5>
- Nasi-Kordhishti, I., Hempel, J. M., Ebner, F. H., & Tatagiba, M. (2021). Calvarial lesions: overview of imaging features and neurosurgical management. *Neurosurgical Review*. <https://doi.org/10.1007/s10143-021-01521-5>
- Nayak, L., Abrey, L. E., & Iwamoto, F. M. (2009). Intracranial dural metastases. *Cancer*, *115*(9), 1947–1953. <https://doi.org/10.1002/cncr.24203>
- Newton, H. B. (2008). Skull and dural metastases. *Cancer Neurology In Clinical Practice: Neurologic Complications of Cancer and Its Treatment: Second Edition*, 145–161. [https://doi.org/10.1007/978-1-59745-412-4\\_10](https://doi.org/10.1007/978-1-59745-412-4_10)
- Ozgiray, E., Perumal, K., Cinar, C., Caliskan, K. E., Ertan, Y., Yurtseven, T., ... Oner, K. (2016). Management of Calvarial Tumors: A Retrospective Analysis and Literature Review. *Turkish Neurosurgery*, *26*(5), 690–698. <https://doi.org/10.5137/1019-5149.JTN.12537-15.0>
- Sawaya, R. (1997). Lesions of the calvaria: Surgical experience with 42 patients. *Annals of Surgical Oncology*, *4*(1), 28–36. <https://doi.org/10.1007/bf02316808>
- Stark, A. M., Eichmann, T., & Mehdorn, H. M. (2003). Skull metastases: Clinical features, differential diagnosis, and review of the literature. *Surgical Neurology*, *60*(3), 219–225. [https://doi.org/10.1016/S0090-3019\(03\)00269-6](https://doi.org/10.1016/S0090-3019(03)00269-6)
- Takei, H., Rouah, E., & Ishida, Y. (2016). Brain metastasis: clinical characteristics, pathological findings and molecular subtyping for therapeutic implications. *Brain Tumor Pathology*, *33*(1), 1–12. <https://doi.org/10.1007/s10014-015-0235-3>